



Research Article

JMR 2024; 10(4):97-101

July- August

ISSN:2395-7565

© 2024, All rights reserved

www.medicinarticle.com

Received:07-06-2024

Accepted:25-07-2024

DOI: 10.31254/jmr.2024.10402

Radioprotective effects of a synergistic oral herbal formulation PRA-5 in mice after whole body irradiation

Suresh Jangle¹, Ravindra Karle¹, Parikshit Bansal²

¹ Department of Biochemistry, Dr. B.V.P Rural Medical College, Loni, Maharashtra, India

² ICTG (Innovative Cancer Technologies Group)- A division of Excellion Innovations and Inventions Pvt. Ltd., Chandigarh, India

Abstract

Background: The ionizing radiations are meant to target the rapidly proliferating cancer cells. However, normal cells such as bone marrow, gastrointestinal, and germinal epithelium are susceptible and sensitive to irradiation-induced damage. This study evaluated the protective effects of a synergistic oral herbal formulation PRA-5 on intestine and testes in mice after single dose whole body irradiation. **Materials and Methods:** Eighteen adult male Swiss albino mice (average age, 5 weeks) and body weight 25 ± 2 g were randomly divided into three groups – Group I (control group), Group II (single dose irradiation of 4 Gy on day 0), and Group III (PRA-5 250 mg/kg body weight 90 minutes before irradiation + 4 Gy on day 0 and administered orally for next 19 days at same dose i.e. 250 mg/kg body weight). On day 20, one mouse was randomly selected from each group and sacrificed. Specimens of small intestine and testes were removed, fixed, stained with hematoxylin and eosin, and observed under light microscope. Qualitative assessments were carried out on captured images of the specimens. **Results:** PRA-5 showed radioprotective effects on the intestinal and germinal cells. Compared with Group I, the intestinal cell specimens from mouse had a significant decrease in villus height and the number of total cells/crypts in Group II. In contrast, in Group III (PRA-5 treatment group), the decrease in villus height was not as prominent as Group II. Compared with Group I, the testes specimen from Group II mouse showed significant damage to the seminiferous tubules. However, in Group III, tissue architecture was preserved, indicating protection from radiation-induced damage. Seminiferous tubules showed all stages of maturation of spermatogonia. **Conclusion:** In this pioneering study, we observed that the oral administration of PRA-5 provided protection against radiation-induced damage to the gastrointestinal and germinal cells in mice exposed to whole body irradiation.

Keywords: PRA-5, Irradiation, Radioprotection, Polyherbal oral formulation, Histopathological changes in intestine and testes, Cancer.

INTRODUCTION

Owing to its survival and palliative benefits, radiotherapy is an effective tool for treating cancer and is used widely in the clinical management of cancer [1]. The ionizing radiation deposits high energy in cells, inducing cellular-level damage that ultimately leads to cell death. Normal cells have the ability to efficiently repair this damage and regain normal functional status. However, a lack of such efficiency makes the cancer cells more sensitive and susceptible to damage by these ionizing radiations [1-3]. The ionizing radiation targets cells that have higher proliferative activity and multiply faster; by inducing cellular-level damage, it inhibits the ability of these cells to divide and proliferate. However, normal cells such as bone marrow, gastrointestinal, and germinal epithelium also have high proliferative activity and are susceptible to damage from these ionizing radiations [4, 5].

Radiation damages the hematopoietic and gastrointestinal cells, and it has been observed that low- to moderate-dose radiation exposure could cause acute radiation syndrome in animal models [5]. Testes are the main reproductive organ in males and are responsible for sperm production. Similar to the hematopoietic and gastrointestinal cells, testes have rapidly proliferating spermatogenic cells and are sensitive to radiation-induced injury. The ionizing radiation causes a reduction in the size and weight of the testes, and testicular damage might result in sterility [6-8]. The radiation-induced effects could appear early (within a few weeks) or late (months to years later) [8]. Although one cannot eliminate these adverse events, the use of radioprotective agents is an approach that could decrease the radiation-induced adverse effects on normal cells [9]. Radioprotective agents are defined as “substances that reduce the effects of radiation in healthy, normal tissues while maintaining the sensitivity to radiation damage in tumor cells.” [10].

*Corresponding author:

Prof. Suresh Jangle

Ex-Professor and Head of Biochemistry, Dr. B.V.P Rural Medical College, Loni- 413736, Maharashtra, India

Email:

sureshjangle.pravara@gmail.com

m

PRA-5 is a patented synergistic oral herbal formulation (Indian Patent No. 301192) that provides effective protection against gamma radiation-induced deoxyribonucleic acid (DNA) damage [11]. It also shows antimicrobial, antioxidant, and anti-inflammatory activity [12,13]. A previous clinical study demonstrated the radioprotective effects of PRA-5 in patients receiving chemoradiotherapy for head and neck cancer. The clinical study was based on the analysis of serum samples from the patients and assessed the radioprotective activity using biochemical and hematological markers [14]. The present study was conducted to evaluate the radioprotective effects of PRA-5 in gastrointestinal and germinal cells using a mouse model.

MATERIALS AND METHODS

PRA-5 oral herbal formulation

PRA-5 contains a combination of 100 mg each of hydroalcoholic extract (80% ethanol) of roots of *Withania somnifera* (Ashwagandha), stems of *Tinospora cordifolia* (Giloy or Guduchi); fruits of *Terminalia bellirica* (Behada), rhizomes of *Curcuma longa* (Turmeric) and leaves of *Ocimum sanctum* (Holy basil).

The plant parts were shade dried, powdered individually and subjected to Soxhlet extraction using 80% ethanol. Thereafter, each of the extracts was dried using a vacuum evaporator until a constant weight was obtained. For the present study, 100 mg of each extract was mixed together and dissolved in distilled water to get the desired concentration. This resulting mixture was then administered at appropriate dosage of 250 mg/kg body weight to mice using standard feeding procedure.

Animals

Eighteen adult male Swiss albino mice with an average age of 5 weeks and a body weight of 25 ± 2 g were used in this study. They were housed in a group of six per cage at a temperature of $22 \pm 1^\circ\text{C}$ with a 12 h light–dark cycle (light on 7 a.m.–7 p.m.) and had free access to the food and water for 7 days prior to irradiation.

Experimental Design

During the study, the mice were kept in well-aerated plastic boxes. Movement of mice was minimized by adjusting the size of small compartment. The mice were randomly assigned to one of the three groups:

- Group I – Control (no radiation or treatment)
- Group II – Irradiation alone; irradiated with 4 Gy on day '0' only
- Group III – Irradiation + PRA-5; on day "0", PRA-5 (250 mg/kg body weight) was administered orally; irradiated with 4 Gy after 90 minutes; PRA-5 250 mg/kg body weight per day was administered orally for next 19 days.

The mice in Groups II and III received a single dose of 4 Gy radiation using Theratoron 780C by an Atomic Energy Regulatory Board-approved radiotherapy technician under the supervision of a qualified radiological safety officer. The dose and dose rate were calculated by a qualified medical physicist.

On day 20, one mouse was randomly selected from each of the three groups, fasted, and sacrificed by decapitation. The pathological examinations were carried out as per the methods described by Bancroft and Cook [14]. From each mouse, a part of the small intestine near the stomach within 1 cm was removed and fixed on a glass slide using Bouin's fixative. Testes were also removed and fixed with 10% formalin. Sections (5 μm thick) were cut, fixed on a glass slide, stained with hematoxylin and eosin, and observed under a light microscope. The slides containing the intestine and testes specimens were

observed under a microscope. Images of the specimens were captured, and qualitative assessments were carried out.

All the experimental and animal handling procedures were approved by the Institutional Animal Ethics Committee on the Use of Live Animals in Teaching and Research of Pravara Institute of Medical Sciences, Loni, Maharashtra, India.

RESULTS

Compared with the control group, the intestinal cell specimen from the mouse in Group II receiving irradiation alone had a significant decrease in villus height and number of total cells/crypts, and there was an increase in the goblet cells (Figure 1). The specimen from the mouse in Group III receiving PRA-5 along with radiation too showed that there was a decrease in the villus height and number of total cells/crypts as compared with Group I. However, the decrease was not as prominent as that observed in the specimen of the mouse from Group II (Figure 1). However, the villus height could not be restored to a normal level even after 20 days of treatment.

Compared with the control group, the testes of the irradiated mouse from Group II showed significant damage; the seminiferous tubules were depleted of germ cells. There was evidence of pyknosis, karyolitic, and degenerative changes in germ cells (Figure 2). In the specimen of the Group III mouse, treatment with PRA-5 resulted in preventing major damage to the testes tissue architecture and various cell populations, including spermatogonia, spermatids, and Leydig's cells (Figure 2). Most of the tubules showed all stages of the maturation of spermatogonia.

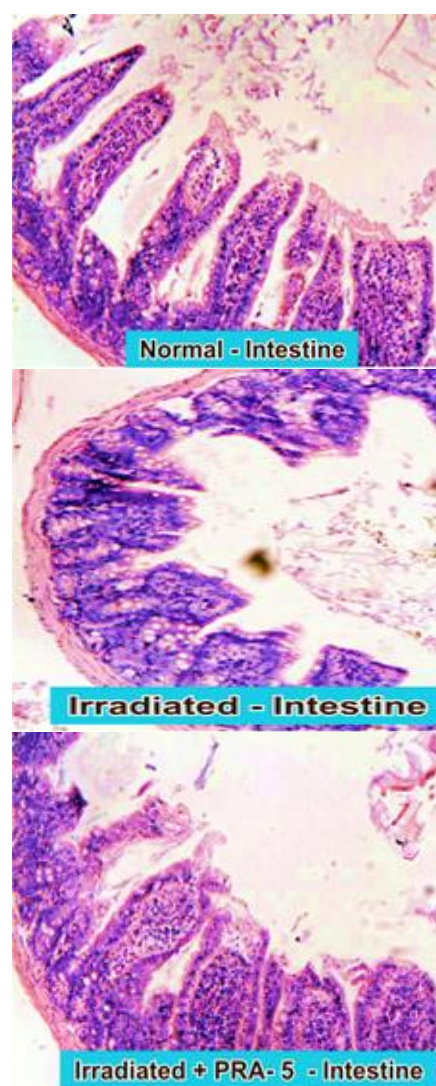


Figure 1: Histopathology of intestine

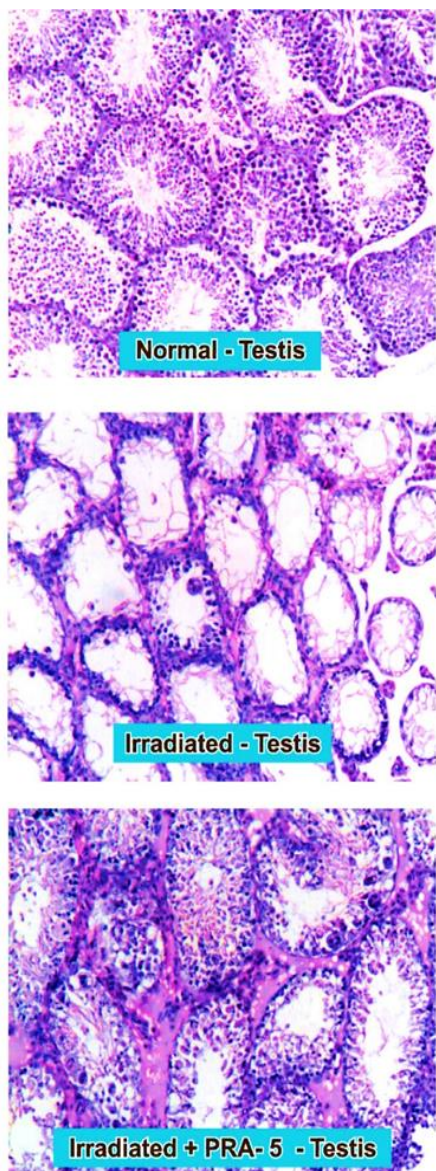

Figure 2: Histopathology of testis

DISCUSSION

The results of this pioneering study in mice showed that oral administration of PRA-5 provides effective protection to the gastrointestinal epithelium and germinal cells from radiation-induced damage. The damage in the intestinal tissues of mice who received PRA-5 + irradiation (Group III) was not as prominent as in the mice receiving irradiation alone (Group II; Figure 1). In testes specimen, it was observed that the PRA-5-treated mice from Group III showed significant protection compared with the mice from Group II who did not receive PRA-5 (Figure 2).

The loss of epithelial cells from the villi might be the reason for the decrease in villus height in the irradiated mice. It is known that radiation could induce the death of crypt epithelial cells and those in the villi. The damage to cells in the proliferative crypt region may be the cause of the reduction in villi height [16–19]. The villus height decreased in both groups. However, the damage to the gastrointestinal epithelium in the PRA-5-treated mice (Group III) was not as prominent as seen in Group II. While there was no major deformation in the structure of the epithelial cells, the villus height did not return to normal even after treatment with PRA-5 for 20 days. PRA-5 administration reduced the severity of radiation-induced changes in the intestinal mucosa, as revealed by the height and structure of the villi. This could be possibly due to less mitotic death as well as the early and least migration of cells from protected crypts to villi before they

are severely affected. The goblet cells increased compared to the control; however, there was no significant difference between Groups I and II. Samarth et al. [20], Bisht et al. [21], and Goel et al. [22] have reported a decrease in crypt cells in irradiated mice. Samarth et al. have reported gastrointestinal protection against gamma radiation using an aqueous extract of *Mentha piperita* in Swiss albino mice. They reported a significant decrease in the height of villi on day 2, and subsequently some recovery was noted at later intervals; however, normalcy was not achieved [20]. Jindal et al. have reported a protective effect of *Rosemarinus officinalis* extract on radiation-induced damage in mice [23]. The results of our study are in conformity with these studies.

Irradiation-related effects led to degenerative changes in germ cells, and the seminiferous tubules were depleted of germ cells. While the damage in irradiated mice was significant, the mice receiving PRA-5 with irradiation seemed to have averted any major damage to the testes. This alludes to the radioprotective effects of the synergistic formulation. Various studies have evaluated the use of herbal extracts as radioprotective agents for managing irradiation-induced effects [23–27]. The antioxidant properties of the phytoconstituents in these tested drugs could inhibit lipid peroxidation and maintain cell permeability in the testes. These radioprotective agents show a significant increase in glutathione, a natural antioxidant [24–29]. High concentrations of glutathione have been reported in rat and mouse testes, [24] and it improves testicular spermatogenesis [29,30]. There is an inverse relationship between glutathione content and lipid peroxidation levels. Irradiation decreases glutathione levels, and the increased peroxidation results in tissue damage [24]. Studies have demonstrated that the herbal formulations could help in restoring the glutathione levels in testes [24–28,31]. The clinical study in patients with head and neck cancer receiving chemoradiotherapy showed that treatment with PRA-5 lowered malonaldehyde and increased total antioxidant status levels in serum [14]. We thus assume that PRA-5 could also enhance glutathione levels and decrease peroxidation levels.

There is extensive evidence for the use of herbs and herbal extracts as radioprotective agents and their beneficial effects in mitigating the side effects of chemotherapy and radiotherapy [22–36]. However, despite this, there are hardly any approved herbal formulations available for prescription as radioprotective agents. In that context, PRA-5 is a well-defined, clinically validated, and duly approved radioprotective oral herbal formulation for use in cancer patients. It has been duly approved for manufacturing and sales under the AYUSH system by the Government of India. Previous studies of PRA-5 have demonstrated the radioprotective, antimicrobial, antioxidant, and anti-inflammatory activities of PRA-5 [11–13]. In an animal study, PRA-5 provided radioprotection at the cellular level as it prevented radiation-induced damage to pBR 322 DNA and lymphocytes [13]. PRA-5 has been evaluated in patients with head and neck cancer for its efficacy and safety in mitigating the side effects of radiotherapy or chemoradiotherapy [14]. The present study is an effort to further elaborate its mechanism of action and generate histopathological evidence with reference to its radioprotective activity. The results of the present study indicate that the radioprotective effects are not limited to a particular organ or system and provide comprehensive radioprotection to the entire body.

Despite all the ongoing research on using chemical and natural or plant-based radioprotective agents, the quest to find an ideal radioprotective agent continues. Herbal medicines have been used for centuries and are considered to be nontoxic, inexpensive, and harmless to humans. The need for cost-effective, safe, and efficient candidates has propelled researchers to look for radioprotective agents from herbs [37,38]. An efficient radioprotective agent provides protection to the majority of organs without any safety concerns. The radioprotective agent should be easy to administer, and oral administration is the most preferred route [37,38]. PRA-5 fits these requirements – it is orally administered, provides systemic and cellular-

level protection against undesired effects of radiation on the entire body, and does not have any undesired side effects.

A larger number of animals, a greater number of specimens, and more standardized parameters to assess the outcome would have made the study even more impactful. We used qualitative parameters, including quantitative outcomes, and measuring the change in villus height and germinal epithelial cells would have boosted the results. Nonetheless, the study supports the outcomes of previous PRA-5 studies. PRA-5 has been shown to possess immunomodulatory and antioxidant properties that may be responsible for its radioprotective action. The results from this study suggest that PRA-5 could be used as a radioprotective supplement in all conditions that require irradiation.

CONCLUSION

Along with cancer cells, normal cells with high proliferative activity are susceptible to radiation-induced effects. Radioprotective agents could help protect these normal cells from irradiation-related adverse events without compromising the effects of irradiation on cancerous cells. PRA-5 has demonstrated beneficial effects in patients receiving chemoradiotherapy for head and neck cancer. In this study in mice, we observed that the use of PRA-5 provided protection to the gastrointestinal and germinal cells from radiation-induced damage. Further clinical investigations are ongoing and will help in substantiating the results from this study.

Acknowledgments

The authors would like to acknowledge medical writing support by Lakshya Untwal (Textometry Pvt. Ltd., India) in accordance with GPP 2022 guidelines (<https://www.ismpp.org/gpp-2022>).

Author Contributions

Suresh Jangle and Ravindra Karle: conceptualization and conduct of the study; data collection and analysis; writing, reviewing, editing the manuscript. Parikshit Bansal: manuscript revisions and formulation related aspects. All authors had complete control over the contents of the manuscript and have read and approved all versions of the manuscript. All authors take complete ownership of accuracy and integrity of the data presented in this manuscript.

Conflict of Interest

The authors declare no conflicts of interest.

Funding

None declared.

ORCID ID

Suresh Jangle: <https://orcid.org/0000-0002-2315-645X>

REFERENCES

1. Baskar R, Lee KA, Yeo R, Yeoh KW. Cancer and radiation therapy: current advances and future directions. *Int J Med Sci.* 2012;9(3):193–199. doi: 10.7150/ijms.3635.
2. Baskar R, Dai J, Wenlong N, et al. Biological response of cancer cells to radiation treatment. *Front Mol Biosci.* 2014;1:24. doi: 10.3389/fmolb.2014.00024.
3. Begg AC, Stewart FA, Vens C. Strategies to improve radiotherapy with targeted drugs. *Nat Rev Cancer.* 2011;11(4):239–253. doi: 10.1038/nrc3007.
4. Little JB. Principal cellular and tissue effects of radiation. In: Kufe DW, Pollock RE, Weichselbaum RR, et al., editors. *Holland-Frei Cancer Medicine.* 6th edition. Hamilton (ON): BC Decker; 2003. Available from: <https://www.ncbi.nlm.nih.gov/books/NBK12344/>
5. Williams JP, Brown SL, Georges GE, et al. Animal models for medical countermeasures to radiation exposure. *Radiat Res.* 2010;173(4):557–578. doi: 10.1667/RR1880.1.
6. Gong EJ, Shin IS, Son TG, et al. Low-dose-rate radiation exposure leads to testicular damage with decreases in DNMT1 and HDAC1 in the murine testis. *J Radiat Res.* 2014;55(1):54–60. doi: 10.1093/jrr/rrt090.
7. Howell SJ, Shalet SM. Spermatogenesis after cancer treatment: damage and recovery. *J Natl Cancer Inst Monogr.* 2005;(34):12–17. doi: 10.1093/jncimonographs/lgi003.
8. Majeed H, Gupta V. Adverse effects of radiation therapy. [Updated 2023 Aug 14]. In: StatPearls [Internet]. Treasure Island (FL): StatPearls Publishing; 2024 Jan-. Available from: <https://www.ncbi.nlm.nih.gov/books/NBK563259/>
9. Smith TA, Kirkpatrick DR, Smith S, et al. Radioprotective agents to prevent cellular damage due to ionizing radiation. *J Transl Med.* 2017;15(1):232. doi: 10.1186/s12967-017-1338-x.
10. Rahgoshai S, Mohammadi M, Refahi S, Oladghaffari M, Aghamiri SMR. Protective effects of imod and cimetidine against radiation-induced cellular damage. *J Biomed Phys Eng.* 2018;8(1):133-140.
11. Jangle SN, Pattan SR. Effect of PRA-5 on elimination of antibiotic resistance in methicillin resistance *S. aureus* (Hospital strain). *Pharmacologyonline.* 2010;3:222–228.
12. Jangle SN, Pattan SR. Radioprotective effects of PRA-5, a polyherbal formulation following whole body exposure to gamma radiations in mice. *Indian Patent.* 2011;301192.
13. Jangle SN, Pattan SR. Radioprotective effect of PRA-5 on radiation induced damage on pBR 322 DNA and lymphocytes. *Indian Medical Gazette.* 2011;92–93.
14. Jangle S, Jain V, Kunkulol R, Bansal P. Evaluating benefits of a polyherbal oral formulation PRA-5 in patients with head and neck cancer undergoing chemoradiotherapy: Results of a pilot study. *J Med Res.* 2024;10(1):12–19. doi: 10.31254/jmr.2024.10104.
15. Bancroft JD, Cook HC. *Manual of histological techniques and their diagnostic applications.* Churchill Livingstone, London, UK, 1984, pp 171–178.
16. Jameus A, Dougherty J, Narendrula R, et al. Acute impacts of ionizing radiation exposure on the gastrointestinal tract and gut microbiome in mice. *Int J Mol Sci.* 2024;25(6):3339. doi: 10.3390/ijms25063339.
17. Kumagai T, Rahman F, Smith AM. The microbiome and radiation induced-bowel injury: evidence for potential mechanistic role in disease pathogenesis. *Nutrients.* 2018;10(10):1405. doi: 10.3390/nu10101405.
18. Shukla PK, Gangwar R, Manda B, et al. Rapid disruption of intestinal epithelial tight junction and barrier dysfunction by ionizing radiation in mouse colon in vivo: protection by N-acetyl-L-cysteine. *Am J Physiol Gastrointest Liver Physiol.* 2016;310(9):G705–G715. doi: 10.1152/ajpgi.00314.2015.
19. Venkateswaran K, Shrivastava A, Agrawala PK, et al. Mitigation of radiation-induced gastro-intestinal injury by the polyphenolic acetate 7,8-diacetoxy-4-methylthiocoumarin in mice. *Sci Rep.* 2019;9:14134. doi: 10.1038/s41598-019-50785-x.
20. Samarth RM, Saini MR, Maherwal J, et al. Mentha piperita (Linn) leaf extract provides protection against radiation induced alterations in intestinal mucosa of Swiss albino mice. *Indian J Exp Biol.* 2002;40:1245–1249.
21. Bisht KS, Prabhu S, Uma Devi P, (2002) Modification of radiation induced damage in mouse intestine by WR 2721. *Ind J Expt Biol.* 2002;38:669–674.
22. Goel HC, Ganguly SK, Prasad J, Jain V. Radioprotective effects of diltiazem on cytogenetic damage and survival in gamma ray exposed mice. *Ind J Expt Biol.* 1996;34:1194-1200.
23. Jindal A, Soyal D, Singh I, Goyal PK. Modification of radiation induced damaged in mice by Rosemarinus officinalis extract. *Pharmacologyonline.* 2006;2:63–75.

24. Gehlot P, Soyol D, Goyal PK (2007) Alterations in oxidative stress in testes of Swiss albino mice by Aloe vera leaf extract after gamma radiation. *Pharmacologyonline*. 2007;1:359-370.
25. Yadav RK, Bhatia AL, Sisodia R. Modulation of radiation induced biochemical changes in testis of Swiss albino mice by *Amaranthus paniculatus* Linn. *Asian J Exp Sci*. 2004;18:63–74.
26. Vyas R, Kesari KK, Slama P, et al. Differential activity of antioxidants in testicular tissues following administration of *Chlorophytum borivilianum* in gamma-irradiated Swiss albino mice. *Front Pharmacol*. 2022;12:774444. doi: 10.3389/fphar.2021.774444.
27. Sharma KV, Sisodia R. Radioprotective potential of *Grewia asiatica* fruit extract in mice testis. *Pharmacologyonline*. 2010;1:487–495.
28. Sharma P, Parmar J, Sharma P, et al. Radiation-induced testicular injury and its amelioration by *Tinospora cordifolia* (An Indian Medicinal Plant) extract. *Evid Based Complement Alternat Med*. 2011;2011:643847. doi: 10.1155/2011/643847.
29. Abdullah F, Khan Nor-Ashikin MN, Agarwal R, et al. Glutathione (GSH) improves sperm quality and testicular morphology in streptozotocin-induced diabetic mice. *Asian J Androl*. 2021;23(3):281–287. doi: 10.4103/aja.aja_81_20.
30. Chen K, Wu L, Liu Q, et al. Glutathione improves testicular spermatogenesis through inhibiting oxidative stress, mitochondrial damage, and apoptosis induced by copper deposition in mice with Wilson disease. *Biomed Pharmacother*. 2023;158:114107. doi: 10.1016/j.biopha.2022.114107.
31. Bhatia AL, Manda K. Role of β -carotene against radiation induced lipid peroxidation in mice testes. *Res J Chem Environ*. 2000;4:59–69.
32. Dowlath MJH, Karuppannan SK, Sinha P, et al. Effects of radiation and role of plants in radioprotection: A critical review. *Sci Total Environ*. 2021;779:146431. doi: 10.1016/j.scitotenv.2021.146431.
33. Haritwal T, Tiwari M, Agrawala PK. Herbal radioprotectors: A mini-review of the current status. *Nat Res Human Health*. 2022;2(2):274–286. doi:10.53365/nrfhh/144880.
34. Shivappa P, Bernhardt GV. Natural radioprotectors on current and future perspectives: A mini-review. *J Pharm Bioallied Sci*. 2022;14(2):57–71. doi: 10.4103/jpbs.jpbs_502_21.
35. Zhang Y, Huang Y, Li Z, Wu H, Zou B, Xu Y. Exploring natural products as radioprotective agents for cancer therapy: Mechanisms, challenges, and opportunities. *Cancers (Basel)*. 2023;15(14):3585. doi: 10.3390/cancers15143585.
36. Ibáñez B, Melero A, Montoro A, Merino-Torres JF, Soriano JM, San Onofre N. A narrative review of the herbal preparation of ayurvedic, traditional Chinese, and Kampō medicines applied as radioprotectors. *Antioxidants (Basel)*. 2023;12(7):1437. doi: 10.3390/antiox12071437.
37. Painuli S, Kumar N. Prospects in the development of natural radioprotective therapeutics with anti-cancer properties from the plants of Uttarakhand region of India. *J Ayurveda Integr Med*. 2016;7(1):62–68. doi: 10.1016/j.jaim.2015.09.001.
38. Joshi Y, Jadhav T, Kadam V. Radioprotective- A pharmacological intervention for protection against ionizing radiations: A review. *Internet J Intern Med*. 2009;8(2):1–11.